


Reproducible Standard Plane Checklist II



Learning points from anatomy

- The femoral head is not round.
- The ossific nucleus is not in the centre
- The acetabulum is not symmetrically deep

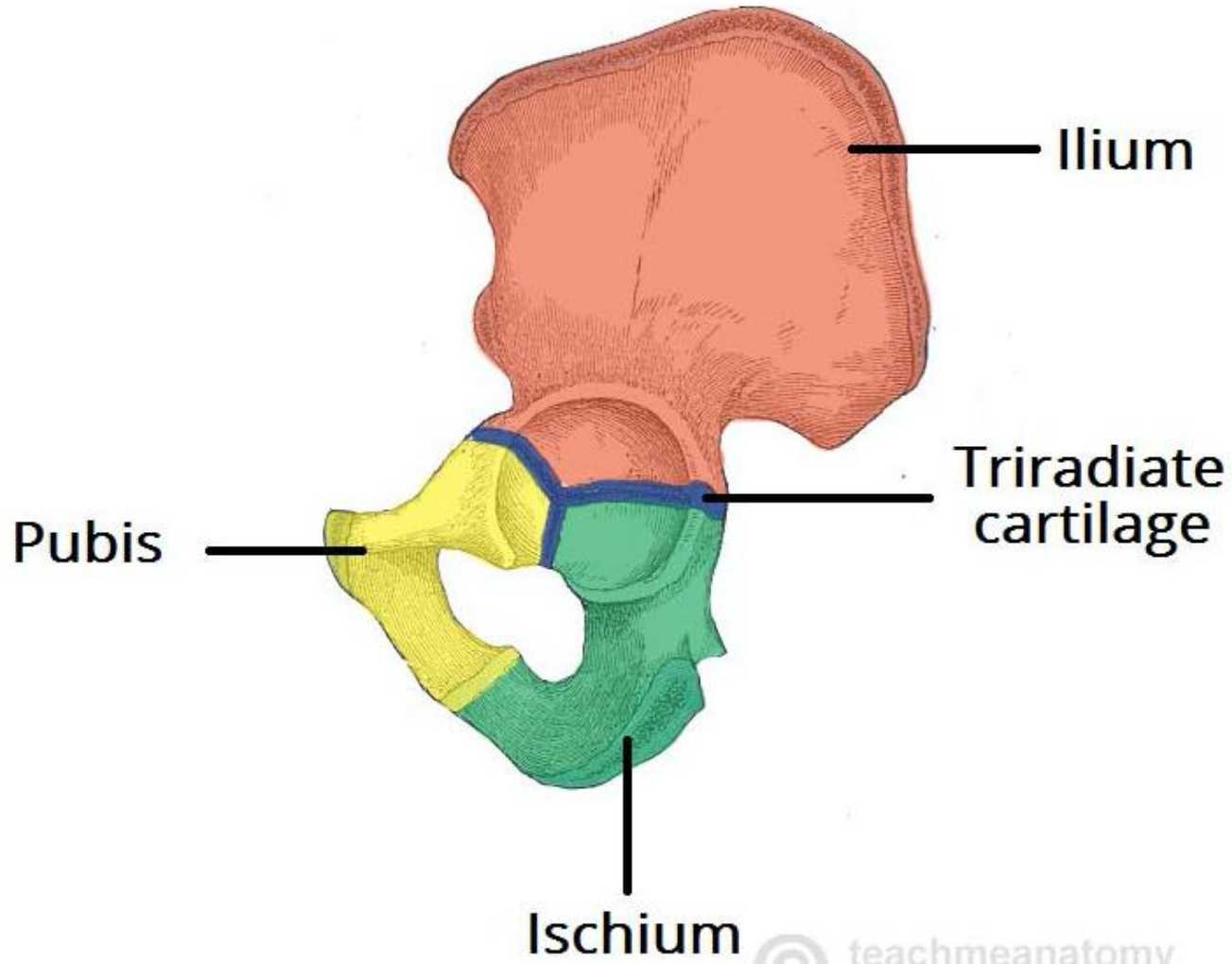
Standard Plane for USS

- Why?

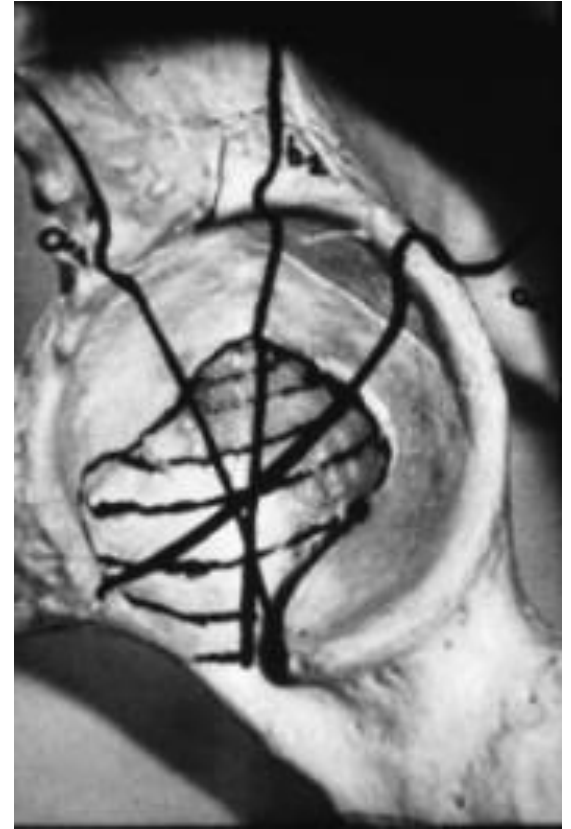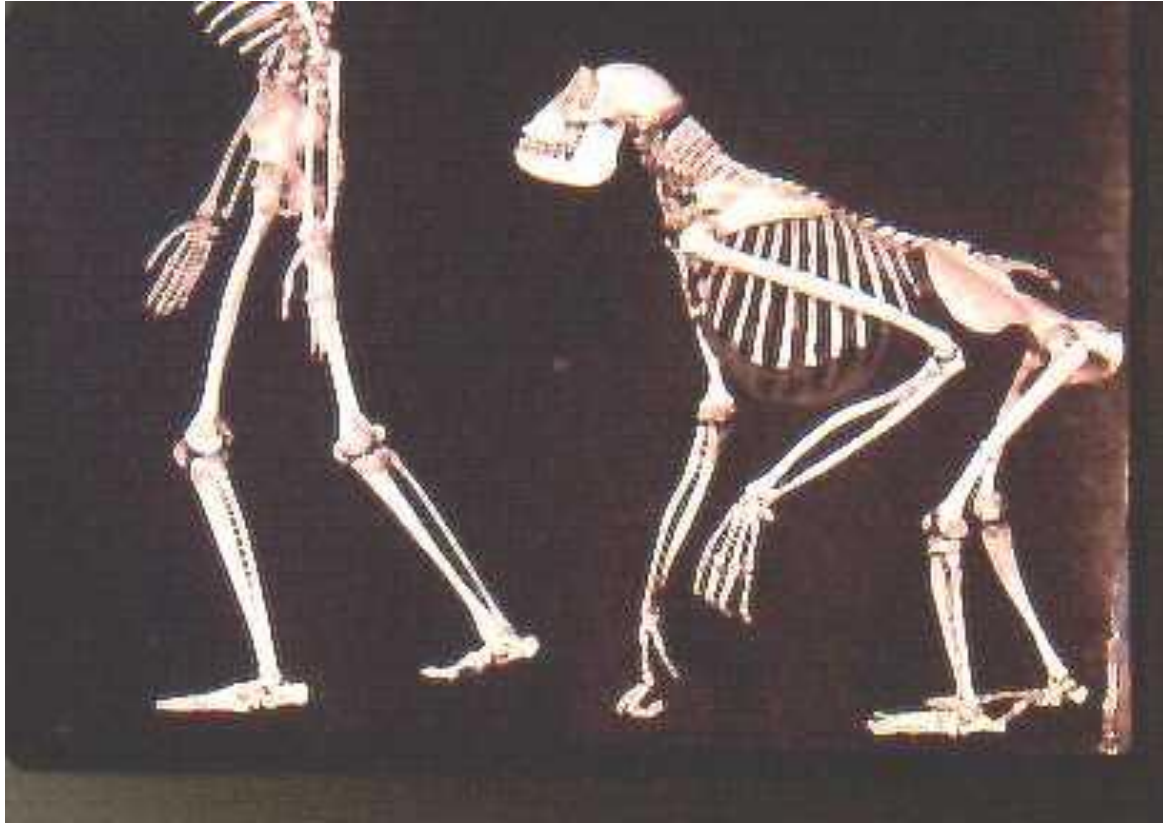
- Need reproducibility

- To define a plane need 3 points

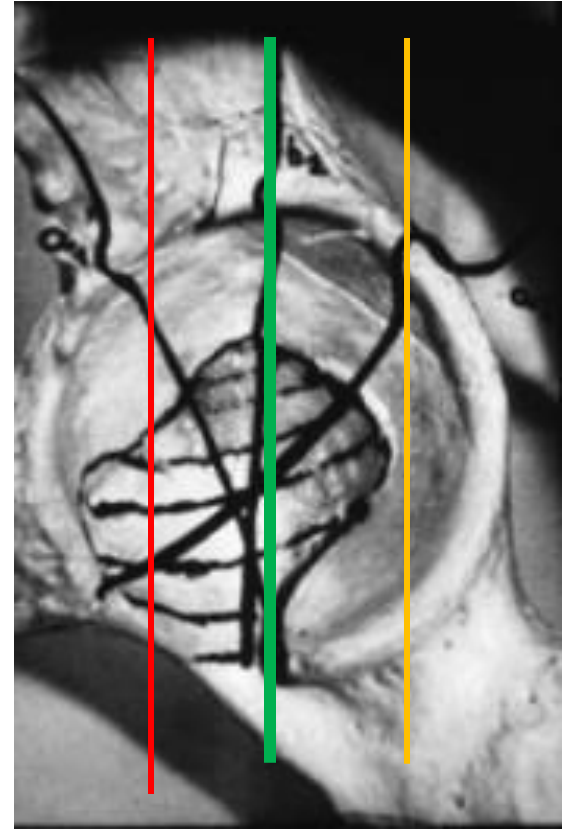
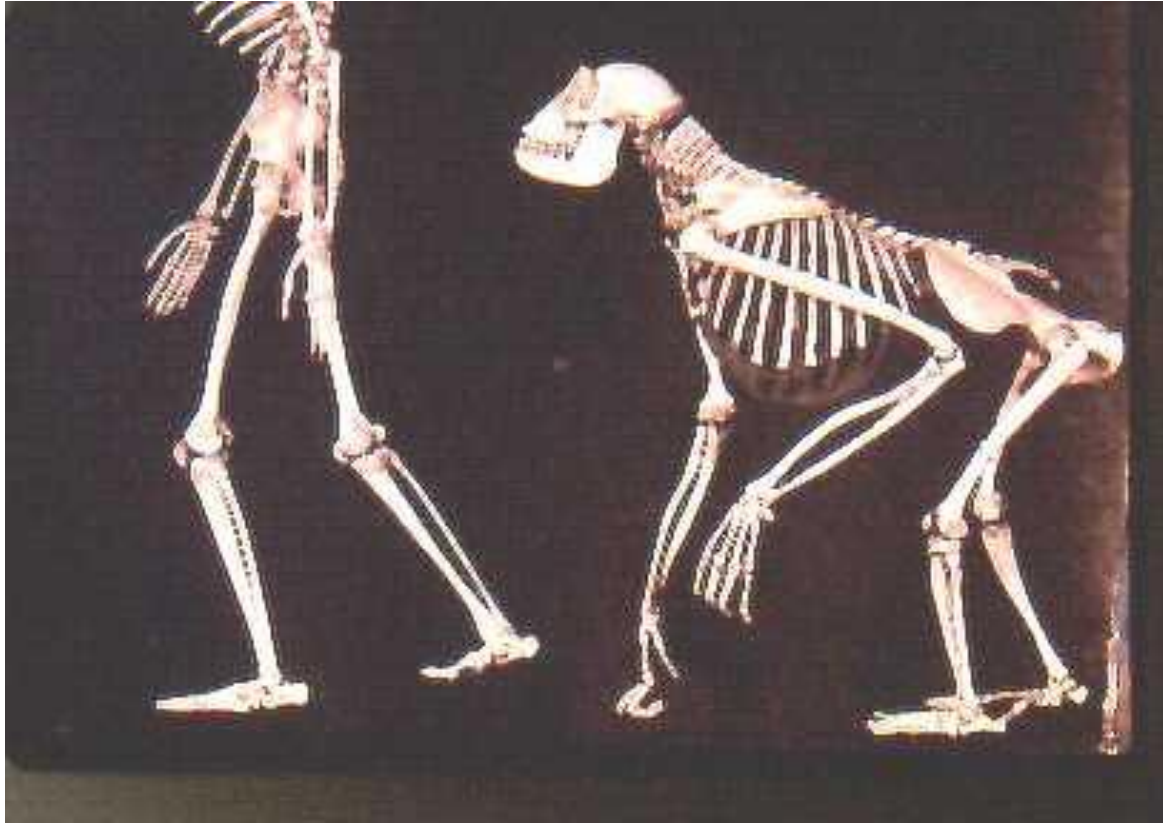
Anatomy of Acetabulum



Evolution

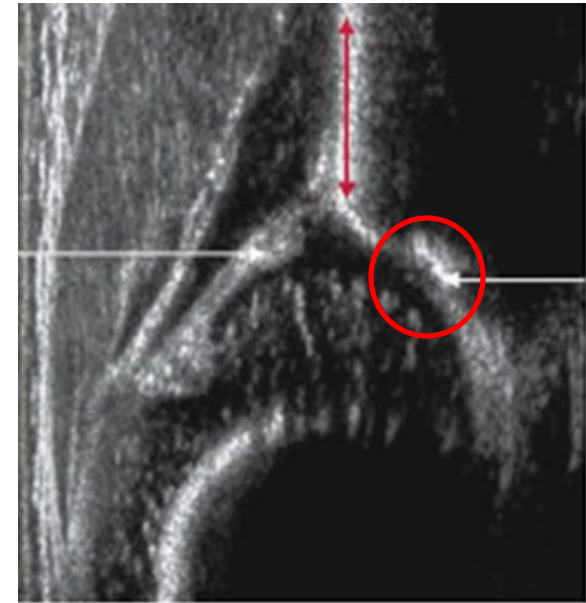
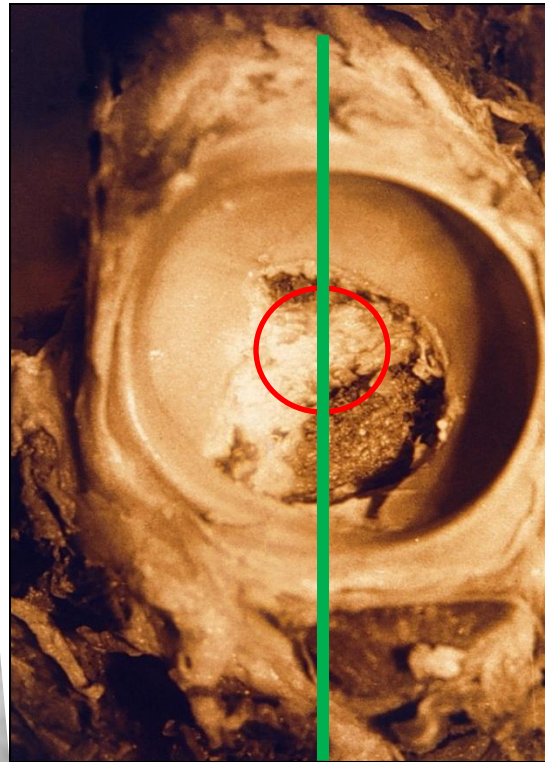
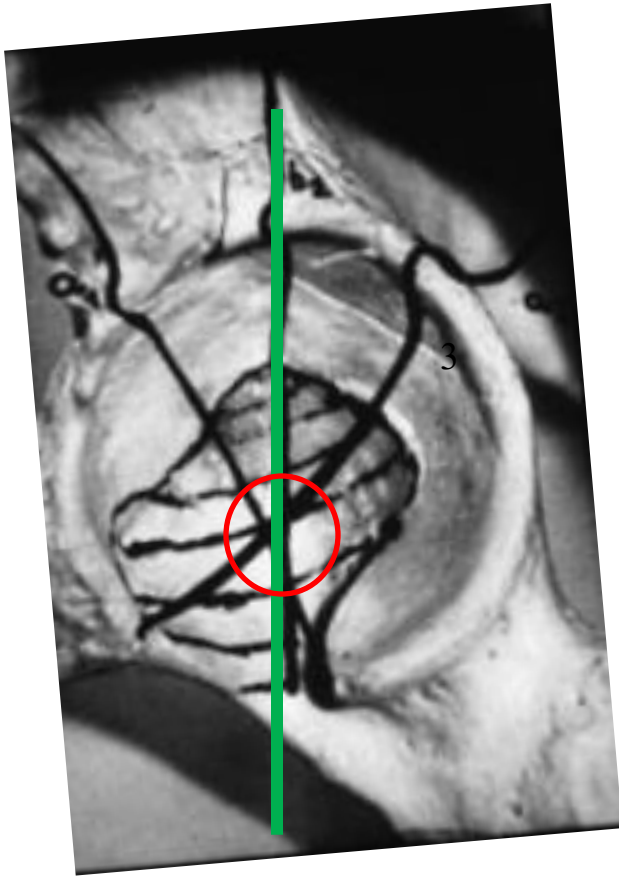


Evolution

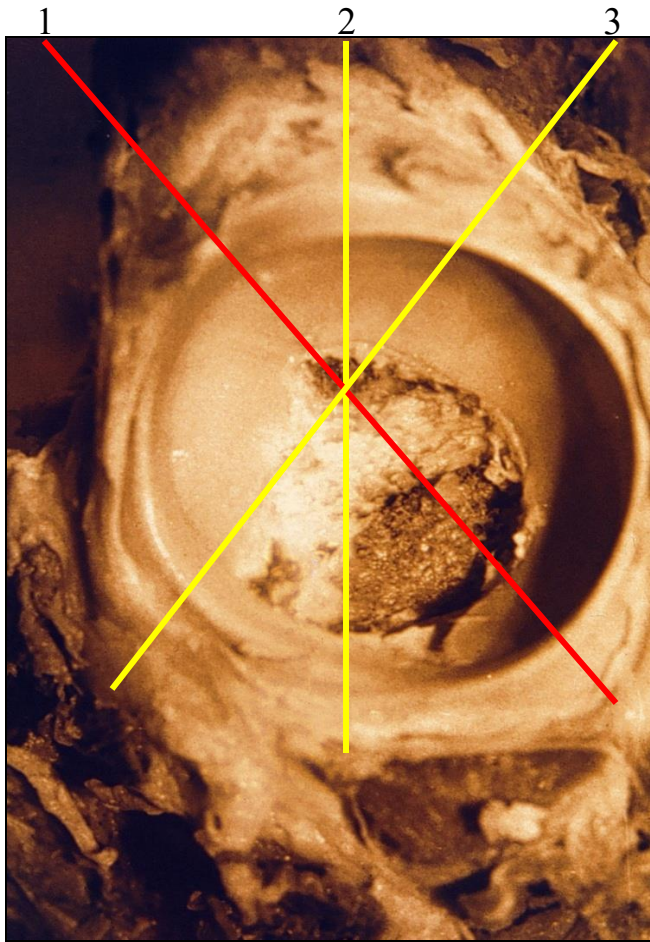


Centre point 1

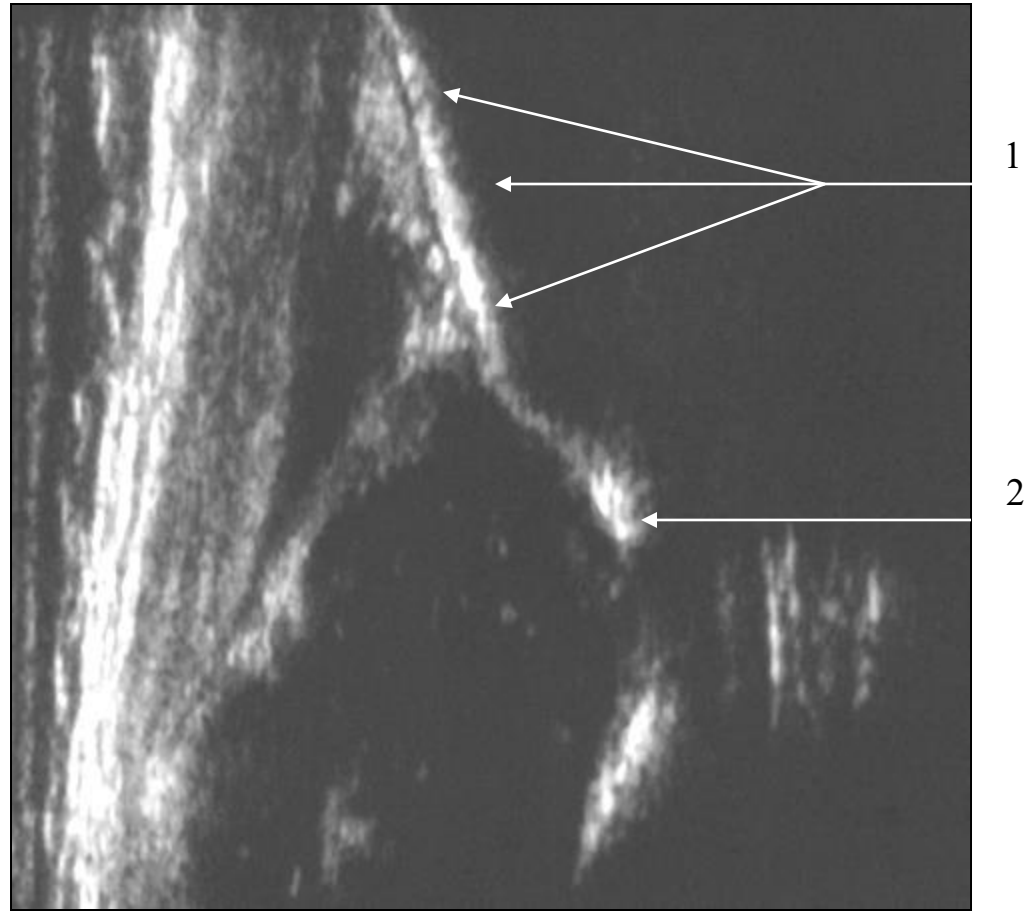
Lower limb of os ilium



Anterior plane

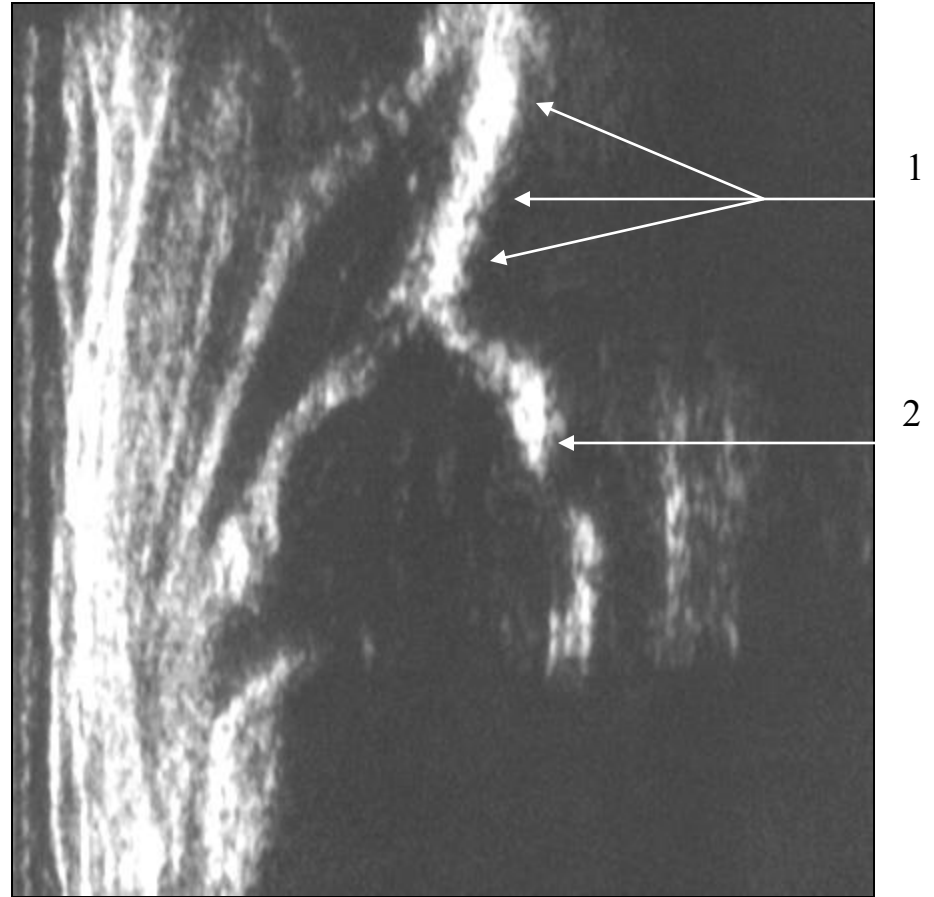
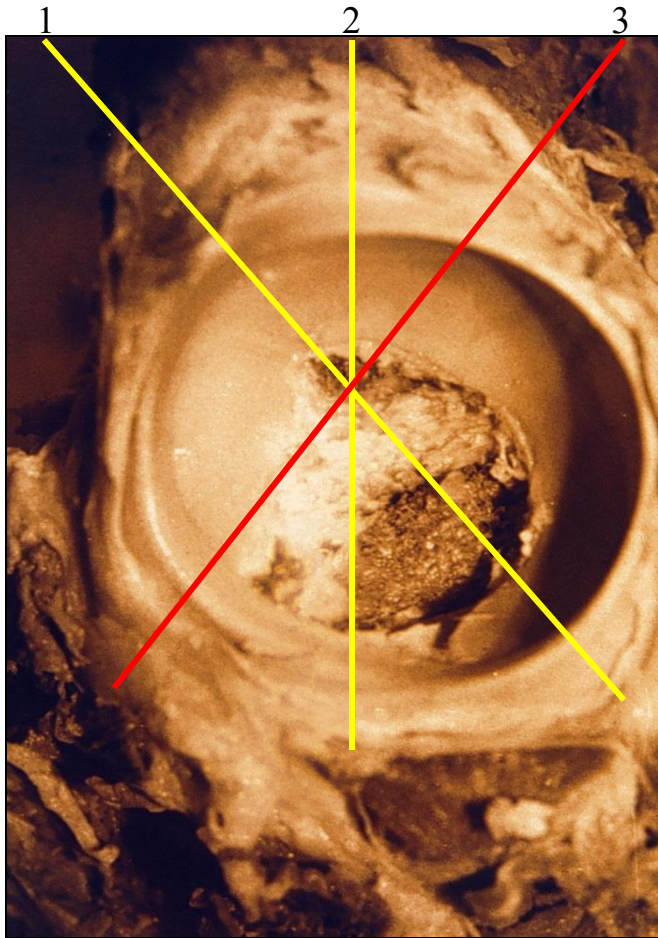


Line 1

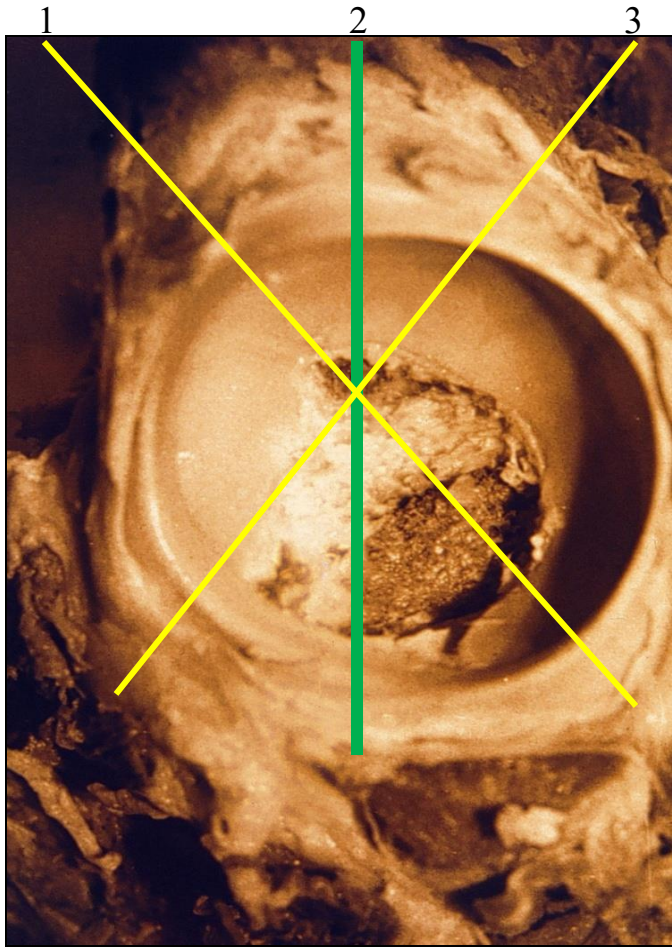


Posterior plane

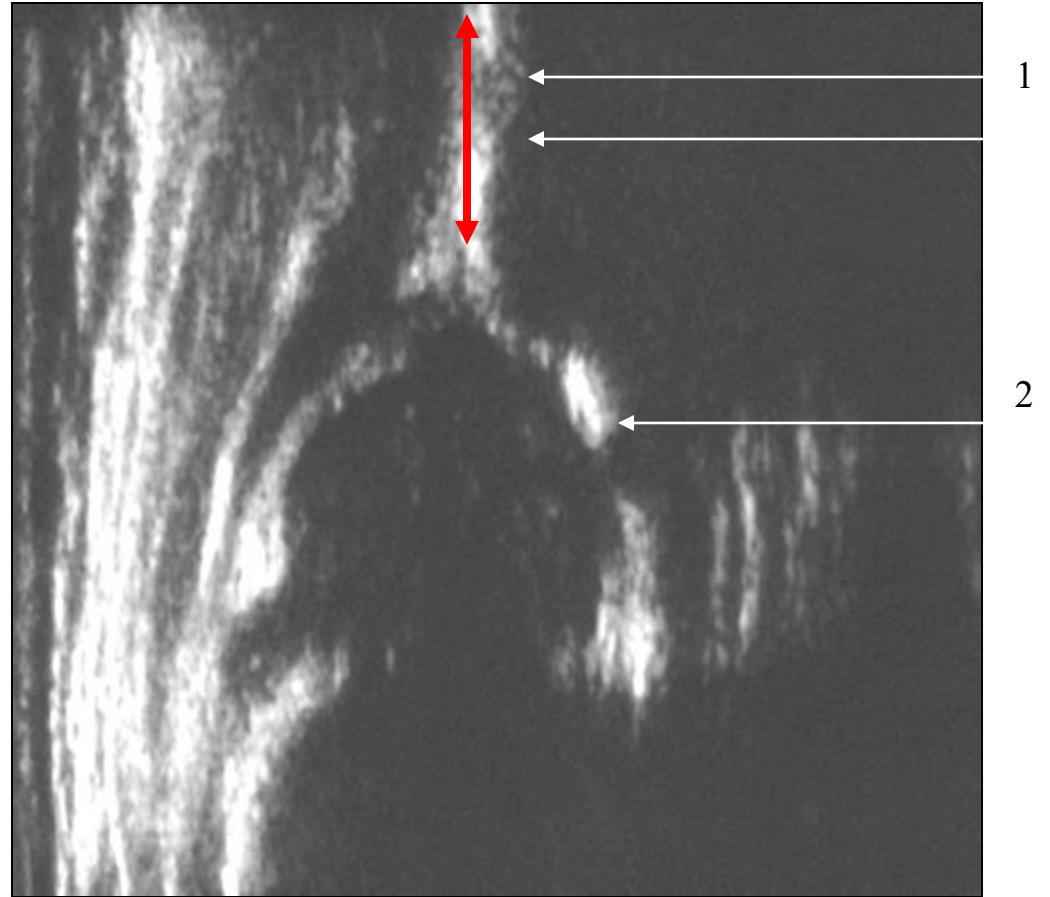
Line 3



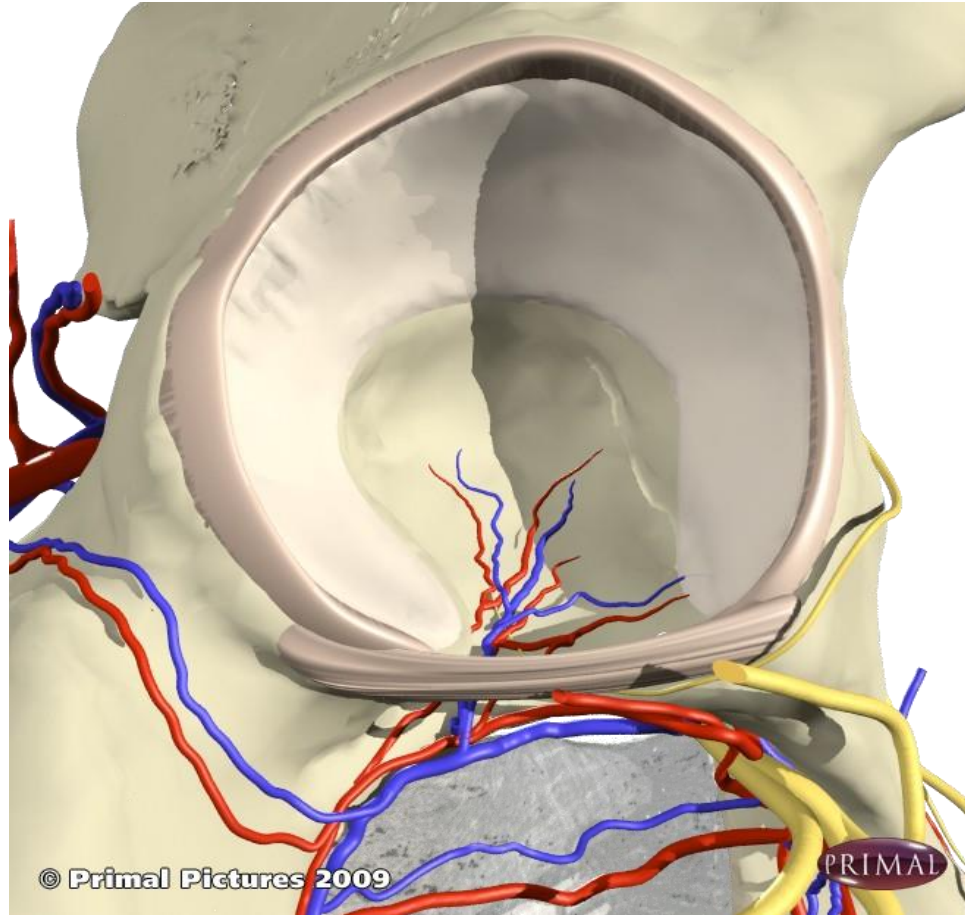
Mid plane 2



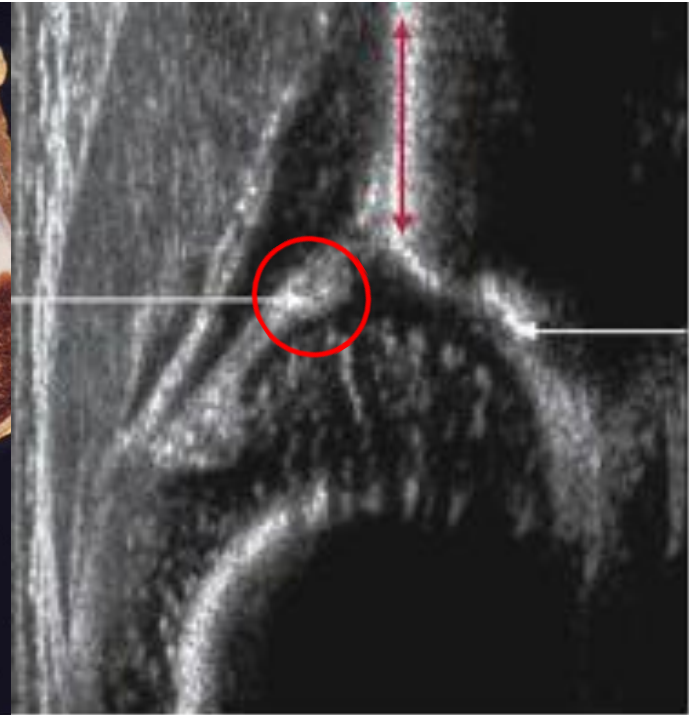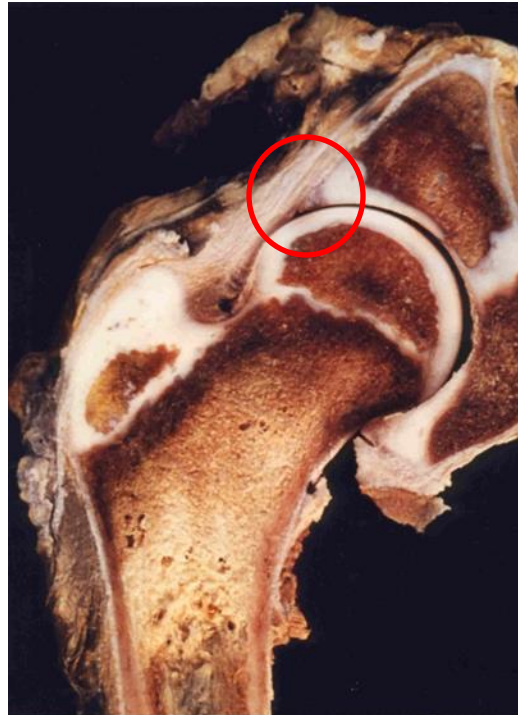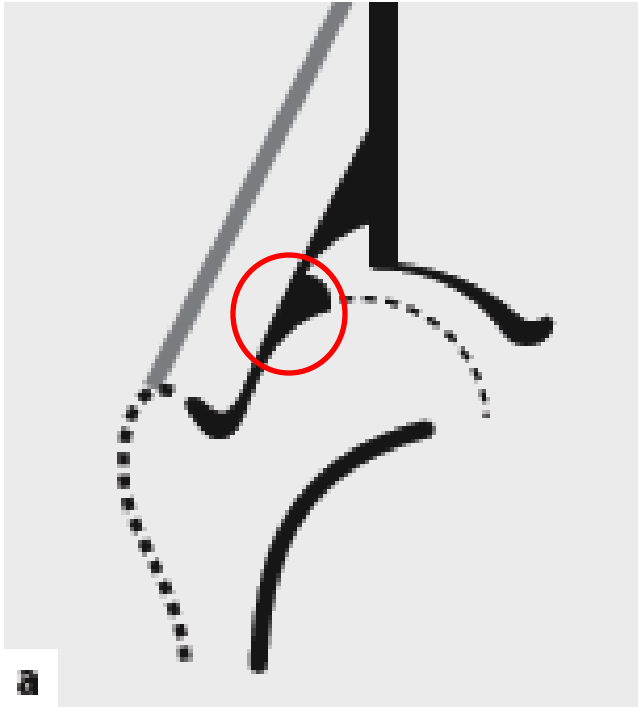
Line 2



Labrum

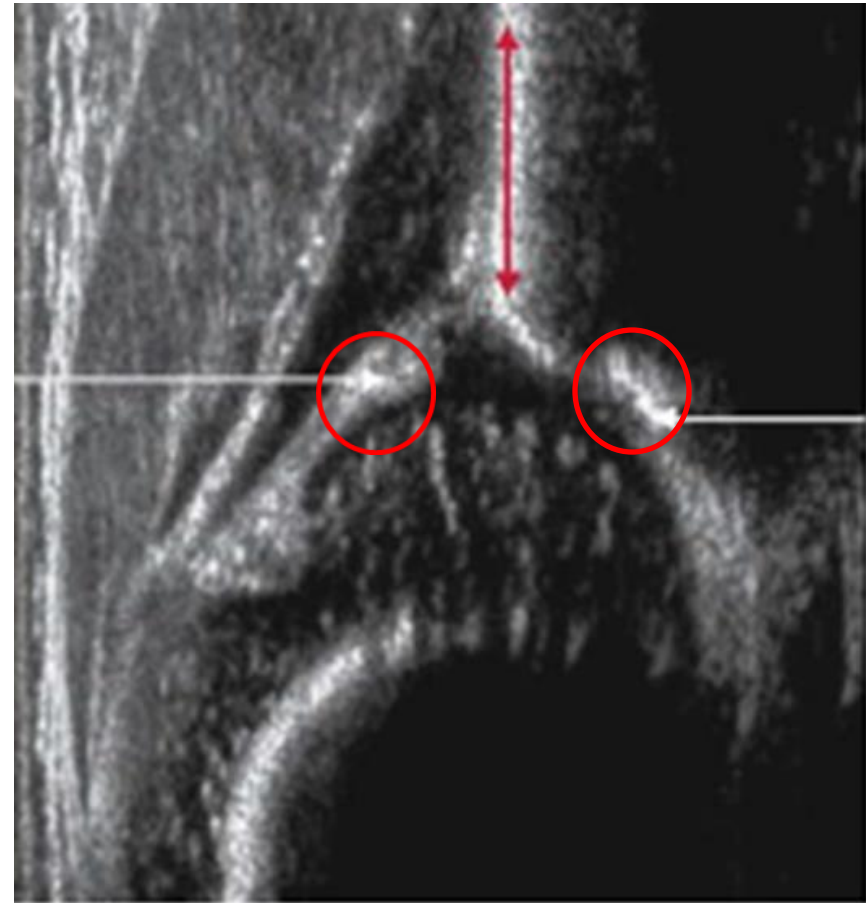

Labrum



Standard Plane

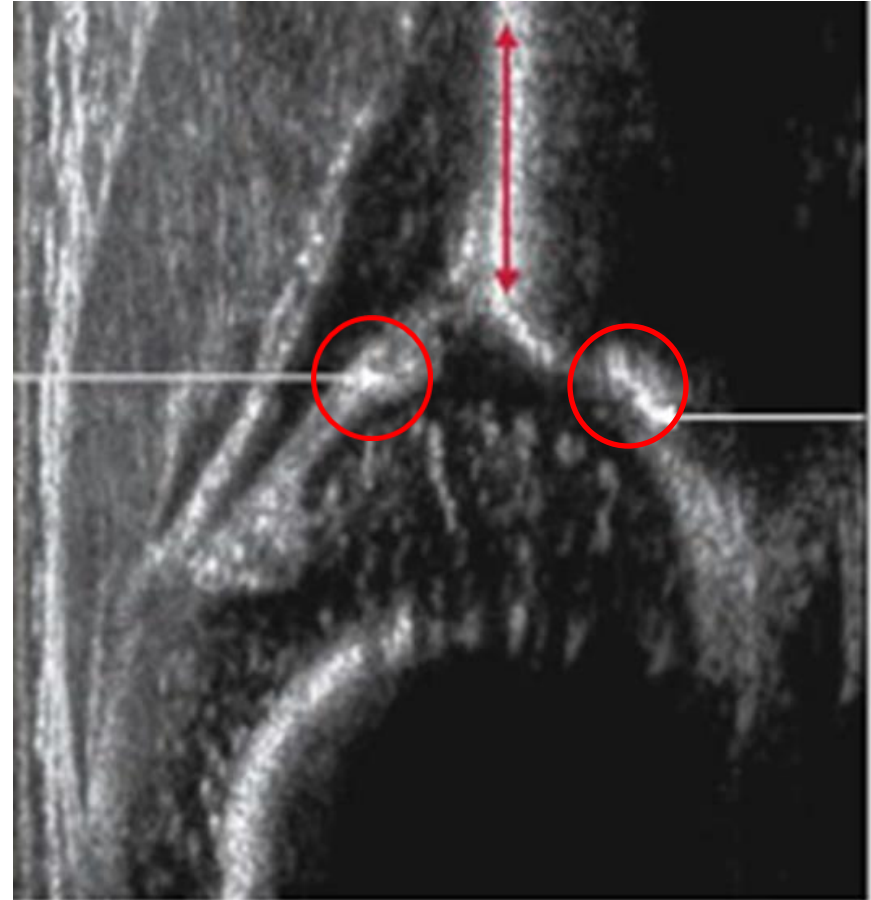
- Lower Limb of ilium
- Mid portion of acetabular roof (plane)
- Labrum



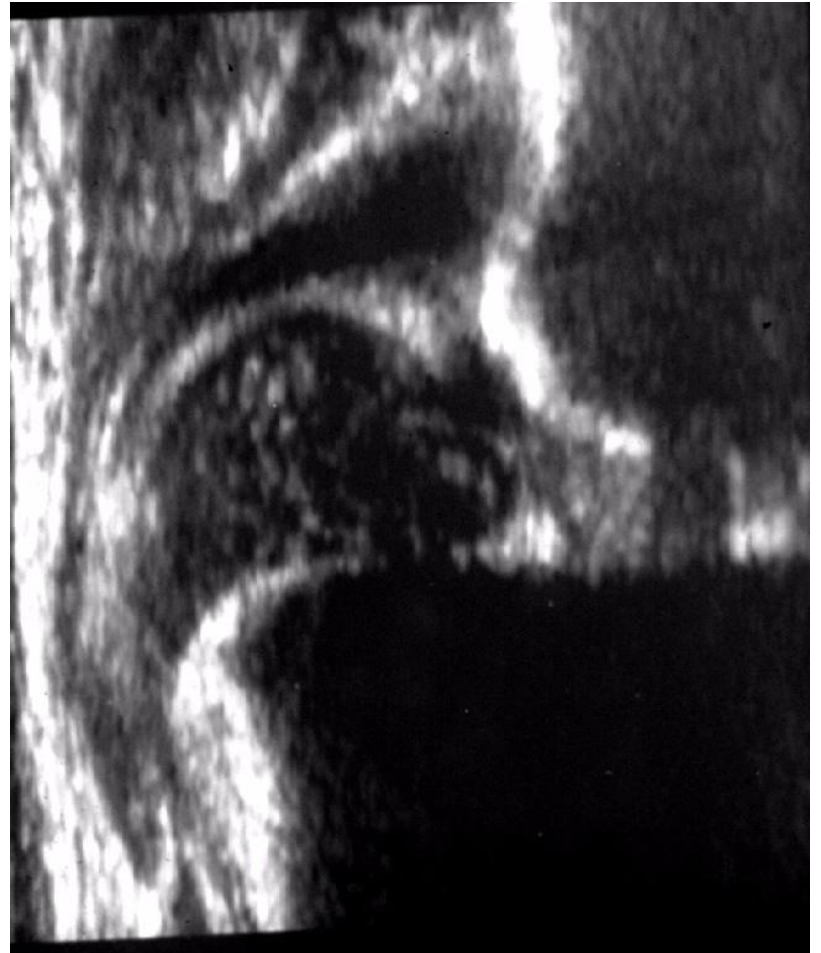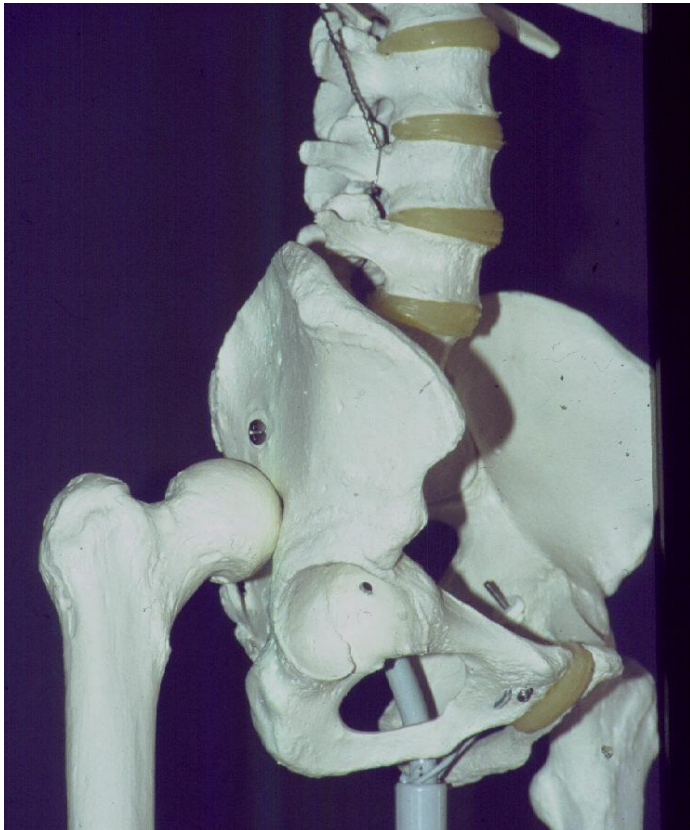Usability check /Checklist 2

- Lower
- Plane
- Labrum

No checklist 2 – no diagnosis
One exception



Exception to checklist 2



Standard Plane

- Lower Limb of ilium
- Mid portion of acetabular roof (plane)
- Labrum

